

Effects of a transdermal testosterone metered-dose nanoemulsion in peri- and postmenopausal women: a novel protocol for treating low libido

Marco Antonio Botelho^{||}, Dinalva Brito Queiroz^{||}, Celso Felício Carvalho^{||}, Allan Freitas^{||}, Gisele Barros^{||}, Julia Gouvea^{||}, Lia Patrus^{||}, Mariane Bannet^{||}, Amália Cinthia Rego^{||}, Irami Araújo-Filho^{||}, Ivaldo Silva^{||}

^{||} Federal University of São Paulo, School of Medicine, Department of Gynecology, São Paulo, Brazil

^{||} University Potiguar, School of Health, Natal, Post-graduation Program in Biotechnology, Brazil

^{||} University Anhembi-Morumbi, School of Medicine, School of Health, São Paulo, Brazil

OBJECTIVE: To investigate the efficacy of a transdermal nanoemulsion testosterone associated with transdermal estrogen therapy as a novel protocol treatment for emergent loss of libido.

METHODS: Twenty-four women, aged 31–75 years (mean age, 51.7), with emergent loss of libido were allocated to treatment with a novel transdermal formulation of 500 µg/day of testosterone (Biolipid/B2[®]-testosterone) for 12 weeks, as part of an open label prospective study on peri- and post-menopausal women. Subjects applied the formulation on the right forearm. Clinical and laboratorial parameters including the sexual complaints; serum concentrations of testosterone, insulin, C-reactive protein, weight, blood pressure; body mass index and waist circumference were compared between baseline and 12 weeks after treatment.

RESULTS: The mean total serum testosterone increased significantly ($p = 0.009$) after 12 weeks of treatment. No adverse or androgenic events were observed. There were positive and significant differences ($p < 0.05$) on sexual complaints, blood pressure, body mass index and waist circumference after transdermal nanoemulsion testosterone treatment.

CONCLUSION: This protocol is effective in increasing testosterone levels in peri- and postmenopausal women with low libido.

KEYWORDS: androgen deficiency; menopause; nanotechnology; transdermal delivery; testosterone; nanoparticles.

Botelho MA, Queiroz DB, Carvalho CF, Freitas A, Barros G, Gouvea J, Patrus L, Bannet M, Rego AC, Araújo-Filho I, Silva I. Effects of a transdermal testosterone metered-dose nanoemulsion in peri- and postmenopausal women: a novel protocol for treating low libido. MEDICALEXPRESS. 2015;2(5):M150503.

Received for Publication on July 2, 2015; First review on July 12, 2015; Accepted for publication on July 24, 2015

E-mail: marcobotelho@pq.cnpq.br

INTRODUCTION

Androgen deficiency leads to different symptoms through the menopause transition.¹ Several studies have shown that the prevalence of sexual disorders among women ranges from 10 to 40%.^{2,3} Transdermal testosterone replacement improves sexual desire and well being in men and women.⁴⁻⁶

The hormone replacement therapy by oral route is frequently related with different adverse events.^{7,8} Recently, the use of nanotechnology has been providing

alternative strategies for the clinical treatment of androgen deficiency.^{7,9} This new technology is present in many fields in medical science and it has been proving to be a strong allied with unique properties for drugs delivery and physiologic absorption.^{10,11}

Over the years, there has been an increasing interest regarding the determination of which symptoms could be used to precisely define testosterone deficiency in women.¹²⁻¹⁵ There is an on going debate for the establishment of an absolute cutoff level for testosterone deficiency in peri- and postmenopausal women.¹⁶ In different studies, testosterone supplementation have been linked to meaningful benefits in the fields of arousal, orgasm and well-being.¹¹⁻¹³

DOI: 10.5935/MedicalExpress.2015.05.03

Recent studies have demonstrated beneficial effects of testosterone supplementation on sexual behavior;¹⁴⁻¹⁵ however there are few data regarding the effects of nanostructured transdermal formulations in restoring or increasing testosterone levels in women.

Data regarding the use of testosterone by peri- and postmenopausal women receiving transdermal estrogen are lacking. Thus, we performed an open-label prospective study to determine the short-term effects of transdermal testosterone therapy (TNT) administered daily by a metered-dose nanoemulsion system, using a nanoemulsion of testosterone (500 µg/day) associated with transdermal estradiol (2.5 mg/day) to treat problems related to sexual desire. The therapeutic effects were evaluated by clinical and laboratorial parameters after a 12 week-follow-up period.

METHODS

Study Design

This was an open label prospective short-term clinical trial study of female patients aged 31-75 years treated for low libido complaints. Eligibility and screening procedures, including breast examinations and collection of blood samples, were performed at a pretreatment visit (4 weeks before study entry). The study was registered at Clinicaltrials.gov: NCT02215434.

Study subjects

The study involved 24 peri- and postmenopausal women aged 43-75 years (mean age: 51.7). Participants were recruited from a Medical Center in Teresina, Piauí, Brazil, and from the general population via announcements over a 6-month period commencing November 2010. The study was completed in May 2012.

Inclusion criteria

Time after the last menstrual cycle and estradiol serum level less than 35 pg/mL. Included participants had the following characteristics: a body mass index between 18 and 27 kg/m², diminished libido, sexual behavior complaints and no evidence of clinical depression. All included participants were in general good health based on history and physical examination.

Exclusion Criteria

The exclusion criteria were: patients (i) with a past history of neurological disorder; (ii) with poor feelings for their partner; (iii) who had received pharmacotherapy for depression within 8 weeks of screening; (iv) who were taking medication known to interfere with normal sexual function (such as α-blockers and β-blockers); (v) who had ever used androgen therapy, (vi) who had recent psychiatric

or systemic illness, (vii) uncontrolled hypertension (blood pressure > 160/95mmHg), (viii) unstable cardiovascular disease, (ix) genital bleeding, (x) acne, (xi) dyspnea, (xii) depression, (xiii) use of psychoactive medications, (xiv) alcohol excess consumption or (xv) any other drug abuse. Throughout the treatment period, participants were additionally excluded if they developed a clinically significant abnormal physical finding or if any adverse event had occurred that made continuation unsafe, as determined by the investigator. Women who commenced any other systemic hormonal therapy were also excluded.

Nanoemulsion Preparation

The nanoemulsion was developed at the Department of Analytical Chemistry (Laboratory of Advanced Materials) at the Federal University of Ceará in association with the Laboratory of Chemistry Technology at the Ceará Institute of Technology. Testosterone and estradiol were purchased from Sigma Aldrich. The formulations of hormone (testosterone or estradiol) plus penetration enhancer (Biolipid/B2[®]) were prepared and the following mass ratios were obtained: testosterone 500µg + Biolipid/B2[®] and estradiol 2.5 mg + Biolipid/B2[®] (Evidence Pharmaceuticals, Sao Paulo/SP, Brazil).

Particle size Z-average and physical stability

Particle size analysis was performed by dynamic light scattering, also known as photon correlation spectroscopy, using a particle size analyzer (Zetasizer Nanoseries-ZS90 (Malvern, UK)). Prior to the measurements, all samples were diluted (1:360) using Milli-Q water to yield a suitable scattering intensity. Dynamic light scattering data were analyzed in disposable sizing cuvettes at a laser wavelength of 633 nm, 25°C, with a fixed light incidence angle of 90°. The mean hydrodynamic diameter (Z-average) and the polydispersity index were determined as a measure of the width of the particle size distribution. The Z-average and polydispersity index of the analyzed samples were obtained by calculating the average of 13 runs. Measurements were performed in triplicate. The mean particle diameter of the testosterone nanoparticles was 232nm. The nanoemulsion of testosterone presented a high negative average zeta potential of -42.8 mV. The physical stability of the testosterone nanoparticles was also evaluated by examining changes in mean particle sizes during storage for 2 months at room temperature. The testosterone nanoparticles did not show statistically significant changes in their mean diameter ($p > 0.05$) when stored at room temperature for 2 months.

Serum Hormone measurements

Blood samples were collected from the subjects early in the morning (drawn before 9 AM) after an overnight fast. All samples were immediately centrifuged. Serum levels of

total testosterone (TT), estradiol (E2), follicle stimulating hormone (FSH), thyroid stimulating hormone (TSH) were measured at baseline and after 12 weeks of treatment by validated methods as described elsewhere.^{11,12}

Serum insulin levels were measured by Chemiluminescence Immunoassay using ECLIA (Roche Diagnostics), with a sensitivity of 0.200 μ IU/ml and intra and interassay CVs of 2.0% and 4.3%, respectively. C-Reactive Protein (CRP) was assayed with a validated high-sensitivity nephelometric method (Dade Behring Marburg, Marburg, Germany). Sensitivity was 0.17 mg/l and intra and inter-assay CVs were 4.4% and 5.7%, respectively. All samples were measured simultaneously in duplicate. The intra-assay variation of the kit was < 10%.

Scanning electron microscope (SEM) assay images

The electron microscopy analysis of the nanoparticles was obtained by a TESCAN SEM equipment (Model VEGA/XMU, Brno, Czech Republic) using an accelerating voltage of the 30Kv. All samples analyzed for SEM were previously sputtered with a ~20nm gold layer in order to obtain the images of the testosterone nanoparticles.

Treatment

During the 12 week period, participants self-administered a daily metered-dose of 0.8g of a nanoemulsion of 500 μ g of testosterone + Biolipid/B2[®] (Evidence Pharmaceuticals, Sao Paulo/SP, Brazil) on the volar surface of the right arm. The same procedure was performed on the volar aspect of the left arm with a nanoemulsion of 2.5mg of estradiol + Biolipid/B2[®] (Evidence Pharmaceuticals, Sao Paulo/SP, Brazil).

Clinical procedures

The first clinical consultation consisted of a brief explanation about benefits and risks of TNT. At consultation, changes in the voice, hirsutism and acne was evaluated by the same physician. Any adverse events were recorded. In addition, during the treatment volunteers were asked to respond questions about sexual complaints or any adverse events. Blood samples were collected at baseline and after 12 weeks of treatment for serum determination of testosterone, estradiol, Thyroid-Stimulating Hormone, Follicle Stimulating Hormone, insulin and C-reactive protein.

Safety Assessment

Safety evaluations included review of adverse events since the last visit, recording of vital signs, assessment of hirsutism using the scale of Lorenzo¹⁷ (which ranges from 0 to 4, with a higher score indicating more hair growth), facial depilation frequency, acne¹⁸ (range, 0 to 3, with an increase in the score of 1 or more considered an adverse event) and breast tenderness (data not shown). The

nanoemulsion application sites were examined for any dermal reaction. Physical examinations, including breast and pelvic examination, were periodically performed. Vital signs, weight, and any vaginal bleeding were recorded at each visit.

Evaluation of sexual and libido complaints

The sexual complaints were assessed by an adapted questionnaire.¹⁴ It includes questions for sexual interest, mood and well-being.¹⁶ The questionnaire form was self-administered at baseline and after 12 weeks of treatment.

Statistical Analysis

All statistical analyses were performed using Graph Pad Prism package for Windows version 3.0 (GraphPad Software, Inc., San Diego, CA, USA). The data are presented as mean \pm SEM or as medians. Differences between baseline and after-treatment were evaluated by Student's *t* test to compare means. Statistical differences were considered to be significant at $p < 0.05$. Categorical variables were compared using chi-square test.

Ethics

All participants gave written informed consent to participate, and the appropriate ethics committees approved the protocol and informed consent form. All participants who completed the third month were invited to continue receiving their assigned treatment. Findings from the extension phase will be reported separately.

■ RESULTS

Patients

A total of 32 women were assessed for eligibility of whom 4 declined to participate; 9 did not meet the eligibility criteria, and 5 could not be contacted (N = 14). The most frequent reasons for ineligibility included being out of the age range, taking excluded medications, coexistent medical conditions or high BMI.

Effects of treatment on anthropometric variables

Table 1 presents the weight, blood pressure, body mass index, waist circumference blood pressure and sexual satisfaction index for the 14 peri- and postmenopausal women before and after 12 weeks of TNT treatment. The changes in weight and were not statistically significant. However diastolic blood pressure decreased significantly.

Effects of treatment on serum hormone concentrations

The average serum of fasting insulin, C-reactive protein, Thyroid Stimuli Hormone (TSH) and Follicle Stimuli Hormone (FSH) concentrations decreased from baseline to week 12 after the treatment with TNT are presented in table 2.

The total testosterone and estradiol levels increased in all women in the TNT group indicating efficacy and compliance with the proposed TNT protocol. There were significant differences ($p < 0.05$) for both hormones levels between baseline vs. after the twelve-week treatment protocol. The mean values for TSH and FSH remained within the menopause range. C-reactive protein decrease with a significant difference, while insulin levels decreased but did not reach statistical significance. Figure 1 shows a sample of a scanning electron microscopic scan highlighting the morphology of testosterone particles. The significant estradiol and total testosterone serum concentration profiles are presented in Figure 2A and B.

Sexual behavior outcomes

At baseline, 38% of all participants considered their sexual behavior as satisfying. This increased significantly to 82% after the twelve-week treatment as shown in Table 1.

Adverse events

No adverse effects were reported by the participants at any time in the study. Hirsutism score did not change significantly with TNT and none of the women developed acne or experienced voice change by self-report or clinical assessment. Application of the nanoemulsion (TNT) was well tolerated, with no women reporting any skin reactions. No serious adverse event occurred.

DISCUSSION

This study was undertaken to evaluate the efficacy of a transdermal nanostructured testosterone therapy in peri- and postmenopausal Brazilian women with sexual complaints using the transdermal nanostructured testosterone therapy associated with estradiol. We have demonstrated that treatment with the 500 µg/day of testosterone in a nanoemulsion, significantly improved sexual desire and reduced sexual complaints.

Recent studies have shown the efficacy and short-term safety of a transdermal testosterone patch delivering 300µg per day for the treatment of hypoactive sexual desire disorder in postmenopausal women who have undergone either surgically induced or natural menopause and who use concomitant estrogen.¹³⁻¹⁵ We found significant improvements in the frequency of satisfying sexual episodes which is similar to those previously shown by others studies when testosterone was administered transdermally.¹⁹

Different studies indicate that sexual activity is one of main factor for a better life and stable relationship between couples. Is it well established that postmenopausal women continue to be sexually active despite sexual complaints.²⁻¹³ Sexual activity is a useful tool to maintain a healthy life. Women were allocated to this study if they reported significant loss of sexual desire. In our judgment, the level of serum testosterone alone, could not be an inclusion criterion, because a single measurement of the

Table 1 - Clinical and anthropometric variables of participants at baseline submitted to TNT on Baseline and after 12 weeks of treatment

	Baseline (n = 14)	12 weeks TNT (n = 14)	Significance
Mean weight ± SD, Kg	57.6 ± 5.28	57 ± 4.86	P = 0.7 ^a
Mean Body Mass Index ± SD, Kg/m ²	22.9 ± 2.27	22.6 ± 2.24	P = 0.8 ^a
Waist Circumference ± SD, cm	82.2 ± 5.86	80.5 ± 4.93	P = 0.4 ^a
Systolic blood pressure (mmHg)	120 ± 9.6	116.4 ± 7.4	P = 0.2 ^a
Diastolic blood pressure (mm Hg)	81.4 ± 9.5	71.4 ± 5.3	P = 0.002 ^{**}
Sexual activity (%)	38	82	P < 0.05 ^b

Values expressed as mean ± SD; P: Difference between Baseline and 12 weeks after TNT; * indicate statistical difference between Baseline and after 12 weeks TNT; Legend for statistical tests: ^a t-test; ^b Chi Square test.

Table 2 - Serum Hormone Concentrations at Baseline and after 12 weeks of treatment

	Baseline (n = 14)	12-weeks TNT (n = 14)	Average paired difference [12-weeks TNT - baseline] (n = 14)	Significance
Fasting Insulin (µU/ml)	4.43 ± 2.25	3.11 ± 1.74		p = 0.09 ^a
C-reactive protein (mg/L)	2.38 ± 2.50	1.14 ± 1.99		p = 0.02 ^{**}
Estradiol (pg/mL)	26.41 ± 22.78	68.25 ± 76.96	+41.84 ± 16.56 [†]	p = 0.02 ^{b***}
Testosterone (ng/dL)	34.34 ± 40.48	98.1 ± 100.2	+63.78 ± 27.50 [†]	p = 0.02 ^{b***}
Thyroid-Stimulating Hormone (µIU/mL)	1.69 ± 0.92	1.36 ± 0.81		p = 0.56 ^a
Follicle Stimulating Hormone (µIU/mL)	54.21 ± 38.51	42.75 ± 35.09		p = 0.02 ^{**}

Values expressed as mean ± SD; [†] Values for [(after 12 weeks) - (Baseline)]: mean ± std error of mean; P: difference between Baseline and 12-weeks TNT. * denotes significance between Baseline vs. 12-weeks TNT; ** denotes significance between [12-weeks TNT - baseline] by paired t-test; Legend for statistical tests: ^a t-test; ^b paired t-test.




Figure 1 - Scanning Electron Microscopic of testosterone particles morphology administered topically in 14 women submitted to TNT during 12 weeks

serum level in women presenting low sexual desire is not the only parameter for diagnosing androgen deficiency.^{3,4}

Previous clinical studies have shown that women treated with testosterone were more likely to report benefits in different aspects related to sexual activity.^{13,14} Regarding, other studies related with testosterone therapy in postmenopausal where taking estrogen failed,²⁰ our findings in this present study are contrary to previous ones^{21,22} that have shown that the concurrent estrogen therapy interferes with exogenous testosterone. A recent study by Botelho et al.⁴ evaluated the comparative effects of transdermal estrogen therapy associated with progesterone. They found that progesterone did not interfere in the results when compared with estrogens alone.

Thus, it is reasonable to understand why transdermal nanostructured estrogen therapy was effective and presented no adverse effects on glucose metabolism; in fact these variables had positive clinical changes over the 12 weeks of treatment. Our findings are consistent with a recent study of transdermal testosterone in premenopausal women with low libido that showed an increase in satisfying sexual episodes with the administration of testosterone therapy.²³

During the treatment period described here, testosterone was delivered consistently, which resulted in biologically active concentrations of testosterone. The zeta potential is an important factor for evaluating the transdermal efficacy of a nanoemulsion. It is a function of the particle surface charge, which modulates the magnitude

of the electrostatic repulsion between particles. In general, particles are considered stably dispersed when the zeta potential is below -30 mV or above +30 mV due to the electric repulsion between the nanoparticles. In the present study the nanoparticles of testosterone presented a strong anionic value. Probably, this is the key to understand the skin absorption process. Other interesting finding of the study is the uniformity of shape and size of the nanoparticles of testosterone the figure taken by Scanning electron microscopy shows a uniform and regular shape of the particles.

There was a minor incidence of androgenic adverse events, with a transient duration; similarly to that observed in other studies there was a slight incidence of acne¹³⁻¹⁵ that was related to higher serum testosterone levels. Probably, this condition may reflect the complexity of receptor sensitivity to testosterone.²⁻⁹ Despite the mild incidence of acne, women report that this event was not seen as an issue.

Breast cancers were not detected in any of our participants. The absence of this condition is probably related to the small sample. However, the possibility of a causal relationship with a larger population must be considered. This is an issue with divergent opinions among researchers.²³⁻²⁵

A recent study suggests that the inclusion of testosterone in women submitted to regimens of estrogen supplementation may play an important role on orgasm²⁵ and the stimulating effects of hormones on the breast.²⁶ The fact that vaginal bleeding was not reported probably reflects the atrophic effect of testosterone on the endometrium;²⁷ during this investigation no endometrial disorders were seen or reported.

The study did not reveal additional safety concerns, but these data should be interpreted with caution, since they involve a small sample. The study was not sufficiently large or long to assess the safety of long-term use of this novel transdermal testosterone nanoemulsion. However, the use of the transdermal nanoemulsion delivering 500 µg of testosterone per day significantly improved sexual desire and decreased distress in peri- and postmenopausal women who were receiving transdermal estrogen therapy; the increase in the frequency of satisfying sexual episodes was modest but appeared to be clinically meaningful. These findings indicate that exogenous nanostructured testosterone therapy, when estrogen is combined seems to be effective in the treatment of hypoactive sexual desire disorder. Additional data are needed to assess the long-term safety of this novel protocol.

■ CONCLUSION

In this study the transdermal testosterone nanoemulsion was effective in improving body mass index and waist circumference in peri- and postmenopausal women, over 12 weeks of

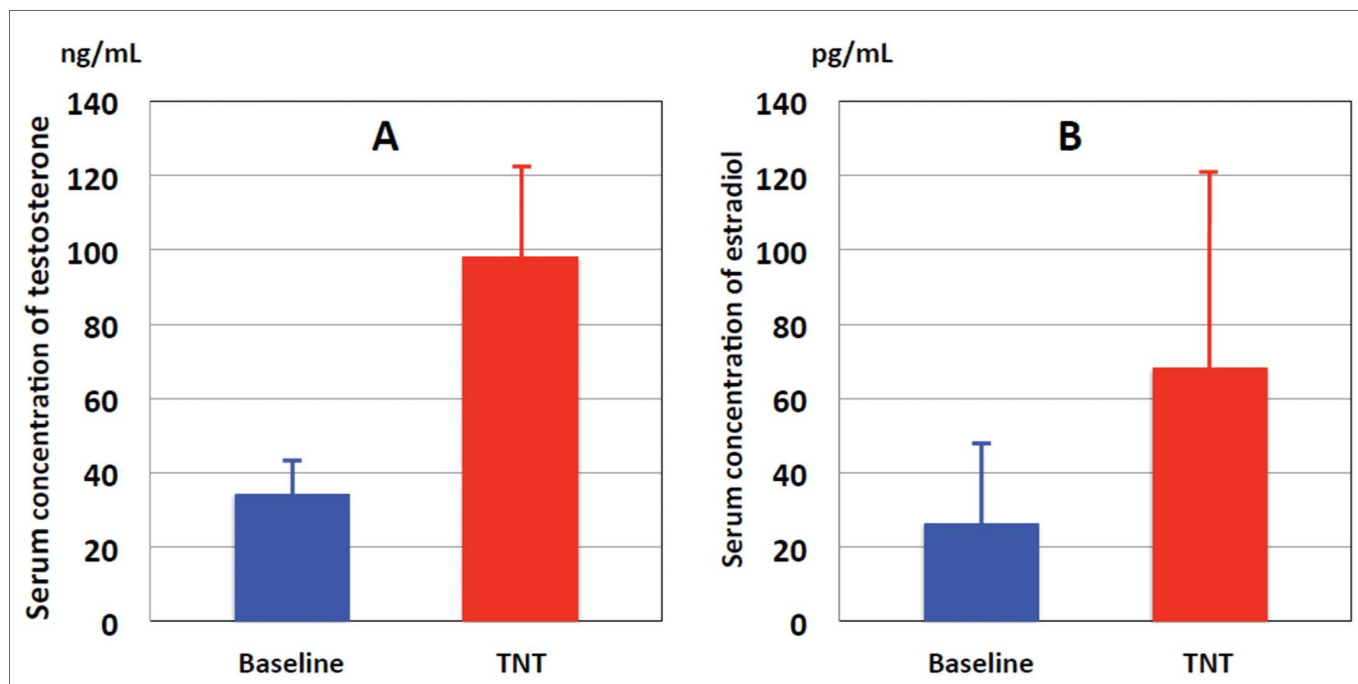


Figure 2 - A: Serum levels of total testosterone from baseline and after 12 weeks of transdermal testosterone metered-dose nanoemulsion treatment. **B:** Serum levels of estradiol from baseline and after 12 weeks of transdermal testosterone metered-dose nanoemulsion treatment.

trial. It increased sexual desire, improved sexual function and improved overall well-being in menopausal women with low libido who were also using transdermal estrogen therapy.

Within the limitations of the study, we have demonstrated significant efficacy of transdermal testosterone nanoemulsion therapy in peri- and postmenopausal women. Our findings may have considerable implications in terms of the psycho-sexual health of menopausal women and merit further investigation through a large randomized controlled study. The protocol used in this study can be seen as an effective strategy for future studies, especially those used to validate transdermal testosterone for menopausal women.

ACKNOWLEDGEMENTS

We gratefully acknowledge the financial support of EDITAL PRO-INFRA (IFCE) and The Brazilian Agency for Scientific and Technological Development (Conselho Nacional de Desenvolvimento Científico e Tecnológico - CNPq) for the approval of a Post-Doctoring Scholarship Proc# 202316/2011-4 and Research Scholarship # 310483/2012-3.

Special thanks to Auzuir Ripardo Alexandria and Jose Wally Menezes (IFCE) for the technical support. Thanks also to Samela Gomes for infra-structural facilities.

CONFLICT OF INTEREST

The authors declare no conflict of interest.

AUTHOR PARTICIPATION

Botelho MA and Freitas A collected the data. Felicio CC, Gouvea J, Barros G, Patrus L, Bannet M, was responsible for the bibliographic review. Botelho MA performed the statistical analysis. Queiroz DB was responsible for acquiring the SEM images and performing the nanosizer analysis. Botelho MA conceived the project and wrote the manuscript. Araújo-Filho I, Rego A and Silva I critically revised the content of the manuscript.

EFEITOS DE NANOEMULSÃO TRANSDÉRMICA DOSIMETRADA DE TESTOSTERONA EM MULHERES PERI- E PÓS-MENOPAUSA: UM NOVO PROTOCOLO PARA O TRATAMENTO DE LIBIDO REDUZIDO.

OBJETIVO: Investigar a eficácia de uma nanoemulsão transdérmica de testosterona associada à terapia com estrogênio transdérmico como tratamento para a perda emergente da libido.

MÉTODOS: Vinte e quatro mulheres, com idade entre 31-75 anos (idade média de 51,7), com perda emergente de libido foram incluídas num protocolo para tratamento de libido reduzida com uma formulação transdérmica de 500 µg/dia de testosterona (biolípido/B2®-testosterona) com 12 semanas de duração, como parte de um estudo prospectivo aberto em mulheres peri- e pós-menopausa. As participantes aplicaram a formulação no antebraço direito. Os parâmetros clínicos e laboratoriais, incluindo as queixas

sexuais foram comparados entre os valores iniciais e 12 semanas após o tratamento. Mediram-se as concentrações séricas de testosterona, insulina, proteína C-reativa, o peso, a pressão arterial; o índice de massa corporal e a circunferência da cintura.

RESULTADOS: A média de testosterona total no soro aumentou significativamente ($p = 0,009$) após 12 semanas de tratamento. Não foram observados efeitos adversos ou androgênicos. Registraram-se reduções significativas ($p < 0,05$) sobre as queixas sexuais, da pressão arterial, do índice de massa corporal e da circunferência da cintura após o tratamento transdérmico com nanoemulsão de testosterona.

CONCLUSÃO: O protocolo mostrou eficácia em aumentar os níveis de testosterona e melhorar a libido em mulheres peri e pós-menopausa com baixa libido.

PALAVRAS-CHAVE: deficiência androgênica, menopausa, nanotecnologia, via transdérmica, testosterona, nanopartículas

■ REFERENCES

1. Zumoff B, Strain GW, Miller LK, Rosner W. Twenty-four hour mean plasma testosterone concentration declines with age in normal premenopausal women. *J Clin Endocrinol Metab* 1995; 80(4):1429-30.
2. Botelho MA, Queiroz DB, Freitas A, Guerreiro S, Umbelino S, Barros G, et al. Effects of a new testosterone transdermal delivery system, Biolipid B2-testosterone in healthy middle aged men: a Confocal Raman Spectroscopy Study. *J Pharm Sci Innov*. 2013;2(2):1-7.
3. Davis SR, van der Mooren MJ, van Lunsen RHW, Lopes P, Ribot C, Rees M, et al. The efficacy and safety of a testosterone patch for the treatment of hypoactive sexual desire disorder in surgically menopausal women: A randomized, placebo-controlled trial. *Menopause* 2006;13(5):387-96.
4. Fugl-Meyer KS, Arrhult H, Pharmanson H, Backman AC, Fugl-Meyer AM, Fugl-Meyer AR. A Swedish telephone help-line for sexual problems: a 5-year survey. *J Sex Med* 2004;1(3):278-83.
5. Davis SR, Moreau M, Kroll R, Bouchard C, Panay N, Gass M, et al. Testosterone for low libido in menopausal women not taking estrogen therapy. *N Engl J Med*. 2008;359 (19):2005-17.
6. Davis SR, Papalia MA, Norman RJ, O'Neill S, Redelman M, Williamson M, et al. Safety and efficacy of a testosterone metered-dose transdermal spray for treatment of decreased sexual satisfaction in premenopausal women: A placebo controlled randomized, dose-ranging study. *Ann Intern Med* 2008;148(8):569-77.
7. Botelho MA, Queiroz DB, Barros G, Guerreiro S, Fachine P, Umbelino S et al. Nanostructured transdermal hormone replacement therapy for relieving menopausal symptoms: a confocal Raman spectroscopy study. *Clinics* 2014;69(2):75-82.
8. Gonzaga LW, Botelho MA, Queiroz DB, Fachine P, Freire R, Azevedo E, et al. Nanotechnology in Hormone Replacement Therapy: Safe and Efficacy of Transdermal Estriol and Estradiol Nanoparticles after 5 Years Follow-Up Study. *Lat Am J Pharm*. 2012;31(3):442-50.
9. Botelho MA, Guerreiro SJ, Queiroz DB, Barros G, Cavalcante M, Souza JMO, Silva AM, Lemos TLG, Quintans Jr L. Depth-scanning confocal Raman for rapid in vivo determination of testosterone concentration profiles in human skin. *MedicalExpress*. 2014;1(1):31-35.
10. Mélot M, Pudney PD, Williamson AM, Caspers PJ, Van Der Pol A, Puppels GJ. Studying the effectiveness of penetration enhancers to deliver retinol through the stratum corneum by in vivo confocal Raman spectroscopy. *J Control Release*. 2009; 138(1):32-9.
11. Botelho MA, Martins JG, Ruela RS, Queiroz DB, Ruela WS. Nanotechnology in ligature-induced periodontitis: protective effect of a doxycycline gel with nanoparticles. *J Appl Oral Sci*. 2010;18(4):335-42.
12. Fooladi E, Bell RJ, Jane F, Robinson PJ, Kulkarni J, Davis SR. Testosterone improves antidepressant-emergent loss of libido in women: Findings from a randomized, double-blind, placebo-controlled trial. *J Sex Med* 2014;11(3):831-39.
13. Simon J, Braunstein G, Nachtigall L, Utian W, Katz M, Miller S, et al. Testosterone patch increases sexual activity and desire in surgically menopausal women with hypoactive sexual desire disorder. *J Clin Endocrinol Metab* 2005;90(9):5226-33.
14. Braunstein GD, Sundwall DA, Katz M, Shifren JL, Buster JE, Simon JA, et al. Safety and efficacy of a testosterone patch for the treatment of hypoactive sexual desire disorder in surgically menopausal women: A randomized, placebo-controlled trial. *Arch Intern Med* 2005;165(14):1582-9.
15. Shifren J, Davis SR, Moreau M, Waldbaum A, Bouchard C, DeRogatis L, et al. Testosterone patch for the treatment of hypoactive sexual desire disorder in naturally menopausal women: Results from the INTIMATE NM1 study. *Menopause* 2006; 13(5):770-9.
16. Panay N, Al-Azzawi F, Bouchard C, Davis SR, Eden J, Lodhi I, Rees M, Rodenberg CA, Rymer J, Schwenkhaugen A, Sturdee DW. Testosterone treatment of HSDD in naturally menopausal women: the ADORE study. *Climacteric*. 2010; 13(2):121-31.
17. Lorenzo EM. Familial study of hirsutism. *J Clin Endocrinol* 1970;31(5):556-64.
18. Palatsi R, Hirvensalo E, Liukko P, Malmiharju T, Mattila L, Riihluoma P, et al. Serum total and unbound testosterone and sex hormone binding globulin (SHBG) in female acne patients treated with two different oral contraceptives. *Acta Derm Venereol* 1984;64(6):517-23.
19. Symonds T, Spino C, Sisson M, Soni P, Martin M, Gunter L, et al. Methods to determine the minimum important difference for a sexual event diary used by postmenopausal women with hypoactive sexual desire disorder. *J Sex Med* 2007; 4(5):1328-35.
20. Alexander JL, Kotz K, Dennerstein L, Kutner SJ, Wallen K, Notelovitz M. The effects of postmenopausal hormone therapies on female sexual functioning: a review of double-blind, randomized controlled trials. *Menopause* 2004; 11(6):749-65.
21. Somboonporn W, Davis SR. Testosterone effects on the breast: implications for testosterone therapy for women. *Endocr Rev* 2004;25(3):374-88.
22. Wierman ME, Basson R, Davis SR, Khosla S, Miller KK, Rosner W, et al. Androgen therapy in women: an Endocrine Society clinical practice guideline. *J Clin Endocrinol Metab* 2006; 91(10):3697-710.
23. Davis S, Papalia MA, Norman RJ, O'Neill S, Redelman M, Williamson M, et al. Safety and efficacy of a testosterone metered-dose transdermal spray for treating decreased sexual satisfaction in premenopausal women: a randomized trial. *Ann Intern Med* 2008; 148(8):569-77.
24. Hankinson SE, Eliassen AH. Endogenous estrogen, testosterone and progesterone levels in relation to breast cancer risk. *J Steroid Biochem Mol Biol* 2007;106(1-5):24-30.
25. Fernandes T, Costa-Paiva LH, Pinto-Neto AM. Efficacy of vaginally applied estrogen, testosterone, or polyacrylic acid on sexual function in postmenopausal women: a randomized controlled trial. *J Sex Med*; 2014; 11(5):1262-70.
26. Zhou J, Ng S, Adesanya-Famuiya O, Anderson K, Bondy CA. Testosterone inhibits estrogen-induced mammary epithelial proliferation and suppresses estrogen receptor expression. *FASEB J* 2000;14(12):1725-30.
27. Zang H, Sahlin L, Masironi B, Eriksson E, Lindén Hirschberg A. Effects of testosterone treatment on endometrial proliferation in postmenopausal women. *J Clin Endocrinol Metab* 2007;92(6):2169-75.